

# Serious oesophageal involvement in a young female patient with pemphigus vulgaris

Miroslava Kloudová<sup>1</sup>, Marcela Kopáčová<sup>1</sup>, Radovan Slezák<sup>2</sup>, Miloslav Salavec<sup>3</sup>, Zdeněk Nožička<sup>4</sup>, Stanislav Rejchrt<sup>1</sup>, Jan Bureš<sup>1</sup>

<sup>1</sup> Clinical Centre, 2nd Department of Medicine, Charles University Teaching Hospital, Hradec Králové, Czech Republic

<sup>2</sup> Department of Dentistry, Charles University Teaching Hospital, Hradec Králové, Czech Republic

<sup>3</sup> Department of Dermatology, Charles University Teaching Hospital, Hradec Králové, Czech Republic

<sup>4</sup> The Fingerland Institute of Pathology, Charles University Teaching Hospital, Hradec Králové, Czech Republic

*Kloudová M, Kopáčová M, Slezák R, Salavec M, Nožička Z, Rejchrt S, Bureš J. Serious oesophageal involvement in a young female patient with pemphigus vulgaris. Folia Gastroenterol Hepatol 2004; 2 (3): 133 - 138.*

**Abstract.** We describe the case of a young female patient suffering from a consequential form of pemphigus vulgaris with extensive involvement of the oesophagus with odynophagia. Upper endoscopy described serious involvement of the oesophageal mucosa. The diagnosis was based on a histological and immunofluorescence examination. The patient has been suffering from a resistant form of posttraumatic epilepsy (she was temporarily treated using carbamazepine and valproic acid ten years ago). The involvement of the oesophageal mucosa is one of the limiting signs of success of the pharmacotherapy.

**Key words:** pemphigus vulgaris, epilepsy, upper GI endoscopy, acantholysis, oesophagus, autoimmune blistering diseases

*Kloudová M, Kopáčová M, Slezák R, Salavec M, Nožička Z, Rejchrt S, Bureš J. Závažné postižení jícnu u mladé nemocné s pemphigus vulgaris. Folia Gastroenterol Hepatol 2004; 2 (3): 133 - 138.*

Popisujeme případ mladé ženy, která trpí závažnou formou pemphigus vulgaris s postižením jícnu manifestující se odynofagií. Horní endoskopické vyšetření popsalo rozsáhlé postižení sliznice jícnu. Diagnóza byla založena na histologickém a imunofluorescenčním vyšetření. Pacientka je současně léčena pro rezistentní formu posttraumatické epilepsie (před deseti lety přechodně léčena karbamazepinem a kyselinou valproovou). Postižení jícnu je jedním z limitujících nálezů úspěšnosti medikamentózní terapie.

**Klíčová slova:** pemphigus vulgaris, epilepsie, endoskopie, akantolýza, jícen, autoimunní puchýřnatá onemocnění

Bullous skin disorders can be debilitating and possibly fatal. Autoimmune blistering diseases include a particular group of pemphigus and pemphigoid disorders, dermatitis herpetiformis and linear IgA bullous dermatosis (4). The onset and course of pemphigus vulgaris is often the result of an interaction between predisposing genetic factors and environmental triggering agents like drug intake (the most common cause in drug-induced pemphigus subtype), physical

agents (heat, UV light, pesticides), viral infection (e.g. the herpes viruses), probably certain diet factors, containing thiols and isothiocyanates with a chemical structure of SH group (25), and even emotional stress (24).

## Case report

We describe the case of a twenty-six-year old female with multiple superficial blisters and confluent

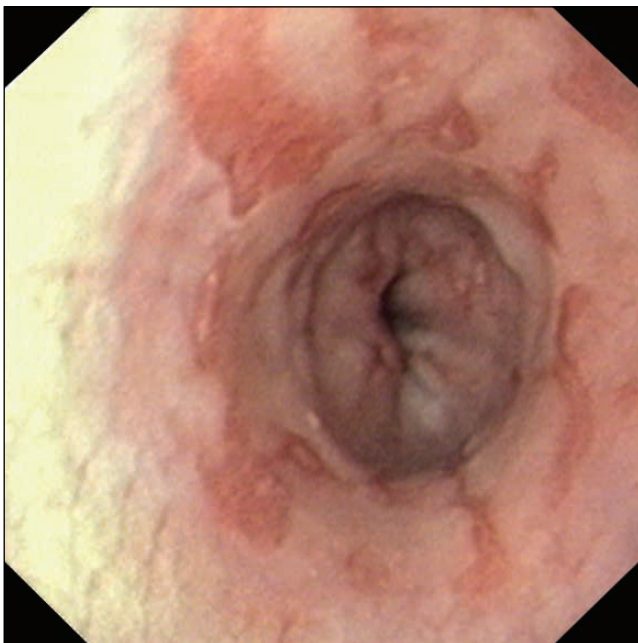


Figure 1  
**Upper GI endoscopy - erosions in the oesophagus originated from burst intraepithelial blisters.**  
**Ezofagoskopie - eroze v jícnu vznikly prasknutím intraepiteliálních puchýřů.**

erosions in the oral cavity and oropharynx, vesicular itching lesions on the entire forearms and a fever of about 38.5 degrees Celsius. Malnutrition with loss of weight developed in the patient due to odynophagia and painful lesions preventing adequate food intake. Since the age of three she has been suffering from severe posttraumatic epilepsy (managed by phenytoin, lamotrigine, primidone, phenobarbital, temporarily by carbamazepine and valproic acid). She has had frequent paroxysms of the grand mal and petit mal. However, she was able to stand and walk, she has learnt to read and write well. She has not been very stigmatized. She underwent an extirpation of the large hepatocellular adenoma one year before onset of the blistering disease. Because of increased serum levels of cholestatic enzymes, hycromone and ursodeoxycholic acid were introduced into therapy one month before admission to our Department. At the same time she visited her dentist because of painful lesions in her mouth. Diagnosis of drug-induced exanthema with blistering was suspected and treated by systemic administration of corticosteroids. Moreover, hycromone and ursodeoxycholic acid treatment was interrupted. Circulating serum drug antibodies were not proved by immunodiffusion according to Ouchterlony. No therapeutical response was observed, only erosions localized on the fore-

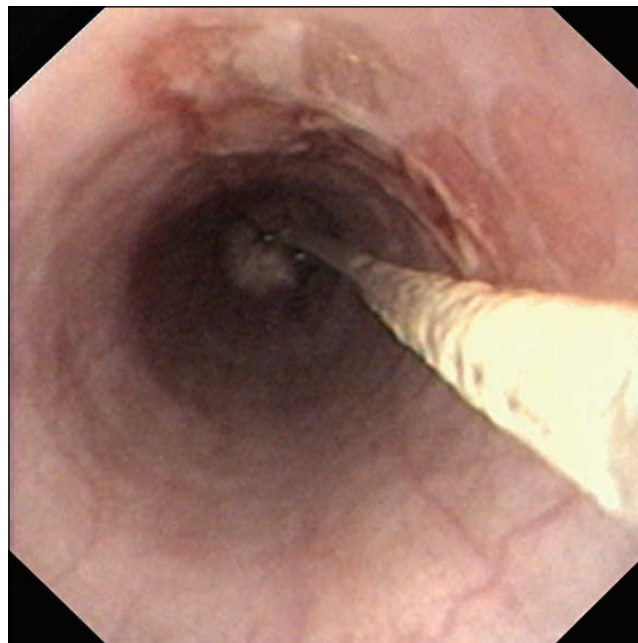


Figure 2  
**Upper GI endoscopy - erosions in the entire oesophagus and fine bore nasojunal tube for total enteral nutrition administration are seen.**  
**Ezofagoskopie - jsou patrné vícečetné eroze v celém jícnu a zavedená tenká nasojejunální sonda k aplikaci úplné enterální výživy.**

arms disappeared. Dysphagia and painful erosions in the oral cavity leading to malnutrition symptoms and malaise were the reason for hospital admission. We started to thoroughly investigate the aetiology of erosions. Allergic reaction and traumatic damage of the oral cavity by epileptic paroxysm were excluded as well as bacterial, viral and mycotic origin by serial negative culture examinations from the oral cavity. The IgM herpes simplex virus antibody serum level was increased. Despite the fact that no positivity of herpes simplex virus diagnosis by PCR examination was confirmed, acyclovir was introduced into the treatment without any response in improvement. Connective tissue disorders were also excluded at the same time (systemic lupus erythematosus, vasculitis, Behçet's syndrome).

In order to exclude inflammatory bowel disease, we performed upper endoscopy. Erosions similar in appearance to the oral manifestations were found at the oesophageal mucosa. However, they did not resemble erosions or ulcers seen in Crohn's diseases (Fig. 1 and Fig. 2). Several biopsy specimens of the oesophageal lesions were taken. Subsequent colonoscopy was normal. Histological examinations of erosions in the oral cavity (Fig. 3) and the oesophagus (Fig. 4) confirmed diagnosis of pemphigus disease. Intraepithelial blistering due to suprabasal acantholy-

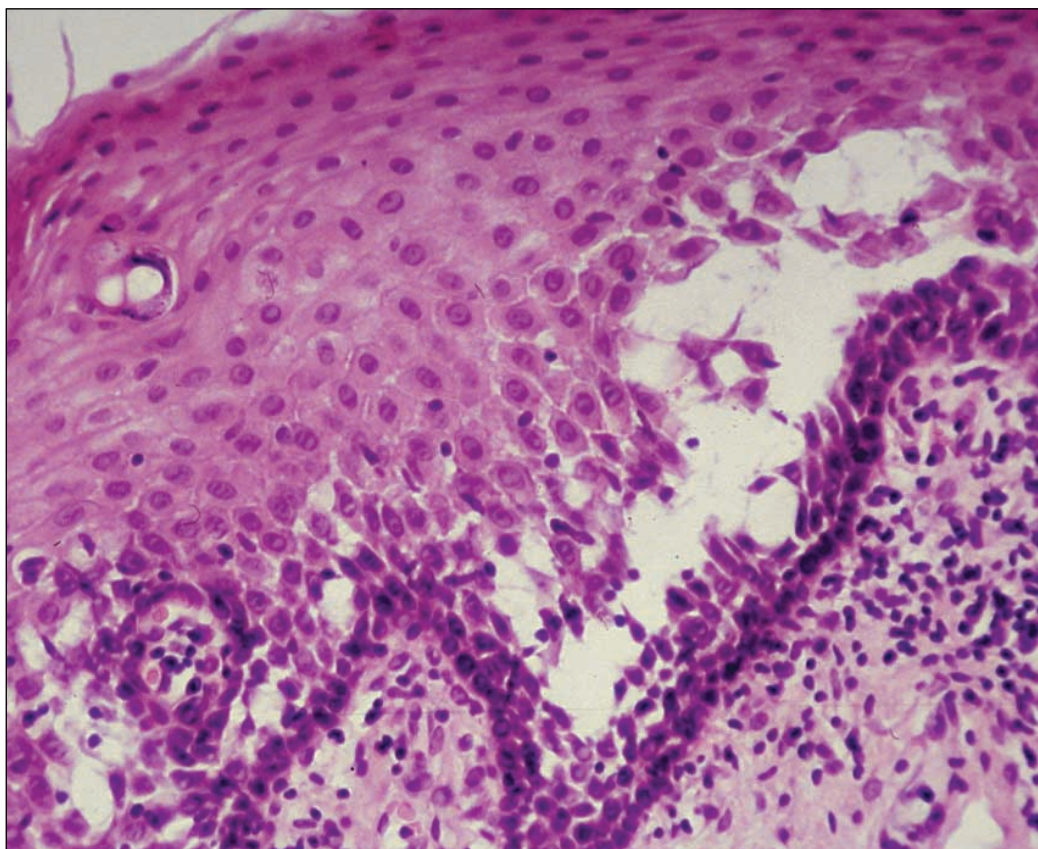


Figure 3  
**Histologic examination:**  
 intraepithelial suprabasal  
 blisters of the oral  
 mucosal epithelium.  
**Haematoxylin-eosin.**  
**Histologické vyšetření:**  
 intraepiteliální  
 suprabazální puchýře  
 epitelu sliznice dutiny  
 ústní. Hematoxilin-eozin.

sis and acantholytic keratinocytes were typically presented. Numerous acantholytic Tzanck's cells were also described in blister cavities. Direct immunofluorescence examination detected positivity in (desmoglein antibodies, cell surface glycoproteins) the intercellular substance (Fig. 5). Erythema multiforme, Stevens-Johnson syndrome, toxic epidermal necrolysis and bullous pemphigoid were excluded in differential diagnosis.

Diagnosis of pemphigus vulgaris was finally established. Clinical diagnosis of pemphigus foliaceus was not suspected, since in pemphigus foliaceus, the disease is epidermal specific and cell-cell detachment occurs within the subcorneal layer of the skin, whereas in pemphigus vulgaris, the diseases affect skin and mucosal epithelia and acantholysis is observed in the suprabasal layer. We also investigated the visceral organs to exclude paraneoplastic pemphigus. No malignancy was proved. Furthermore, the fluorescence pattern did not respond to the typical one for paraneoplastic pemphigus. Glucocorticosteroid treatment was started with five pulses of parenteral methylprednisolone (125 mg daily), and then followed by another five pulses every other day. Enteral nutrition by fine bore nasojejun tube was implemented. Corticosteroids were also applied topically into mucosal erosions.

Partial improvement to the lesion was recorded. We tried to reduce the dosage of phenobarbital and to increase the dosage of lamotrigine gradually. However, the patient exhibited a high frequency of epileptic seizures, so the initial antiepileptic treatment dosage was reintroduced. She continued taking orally administered corticosteroids and oral nutrition was tried, followed by the occurrence of new painful erosions. Enteral nutrition was reestablished and we started with immunosuppressive therapy by azathioprine (2.5 mg per kilogram). No sufficient response was noted, so the dosage of azathioprine was increased to 3 mg per kilogram with concomitant medication of methylprednisolone 1 mg per kilogram. The neurologist decided to partially change the antiepileptic therapy (phenytoin, lamotrigine, primidone, levetiracetam). Seven months of both high-dose immunosuppressive and topical therapy resulted in an effective response. Maintenance therapy required 100 mg of orally administered azathioprine and 6 mg of methylprednisolone per day. Although some erosions did not disappear, she is able to accept a normal oral diet.

## Discussion

Pemphigus encompasses a group of autoimmune blistering diseases of the skin and mucous membra-

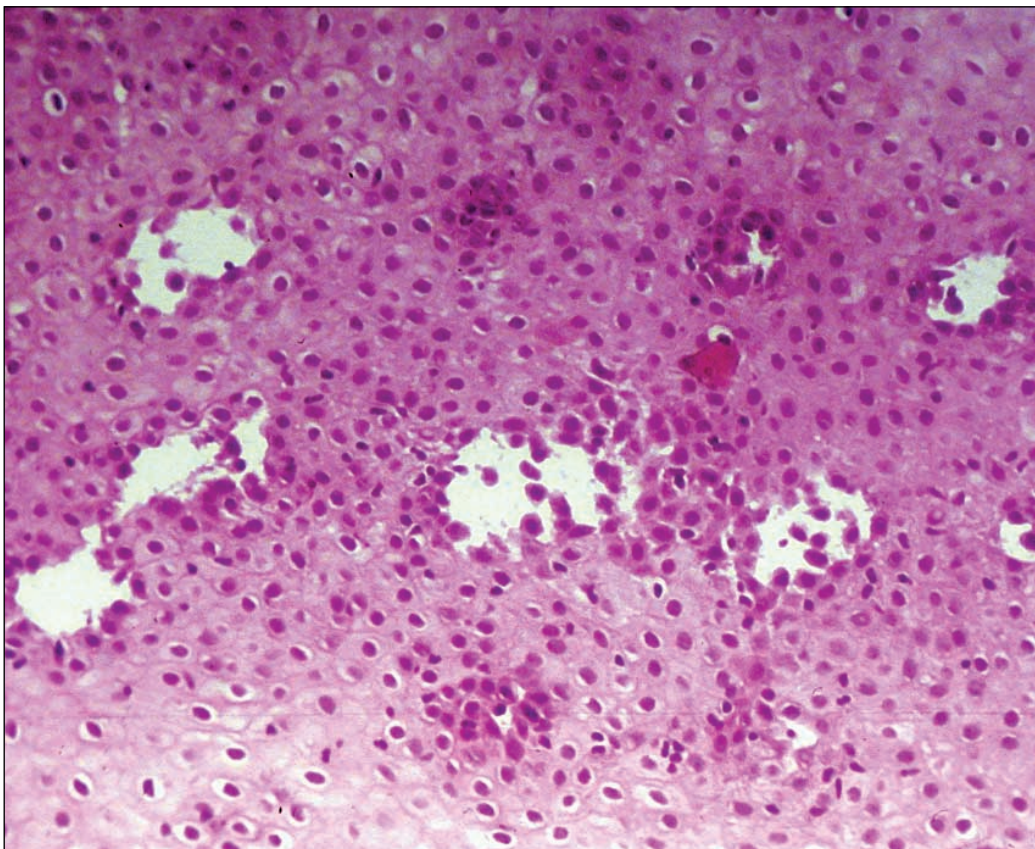


Figure 4  
**Histologic examination:  
 intraepithelial blisters of  
 the oesophageal mucosa.  
 Haematoxylin-eosin.  
 Histologické vyšetření:  
 intraepiteliální puchýře  
 sliznice jícnu.  
 Hematoxilin-eozin.**

nes. Blister formation occurs in the epidermis by the process known as acantholysis, which refers to a loss of cohesion between epidermal cells (9). There are three major types of the pemphigus disease group: pemphigus vulgaris, pemphigus foliaceus and paraneoplastic pemphigus. Pemphigus vulgaris is the most common. It usually occurs in middle-aged and older persons. The age of onset in our patient (26 years) is not a typical one for this disease.

Pathogenic autoantibodies in pemphigus, usually of IgG class are directed against desmoglein, an adhesion molecule (1). We recognize antibodies directed against desmoglein 3, about half the patients having also desmoglein 1 autoantibodies. Furthermore, lack of mucosal involvement in pemphigus foliaceus seems to be due to a much lower expression level of desmoglein 1 than desmoglein 3 (surface antigen in pemphigus foliaceus, desmosomal protein) throughout squamous mucosal epithelia and the presence of desmoglein 3 could be sufficient for cell-cell adhesion with no oral involvement in pemphigus foliaceus patients (28). Clinical phenotype of pemphigus, in particular the balance of skin and oral disease, is determined principally by the quantities of desmoglein 1 and desmoglein 3 autoantibodies, respectively. Oral severity is particularly associated with desmoglein 3

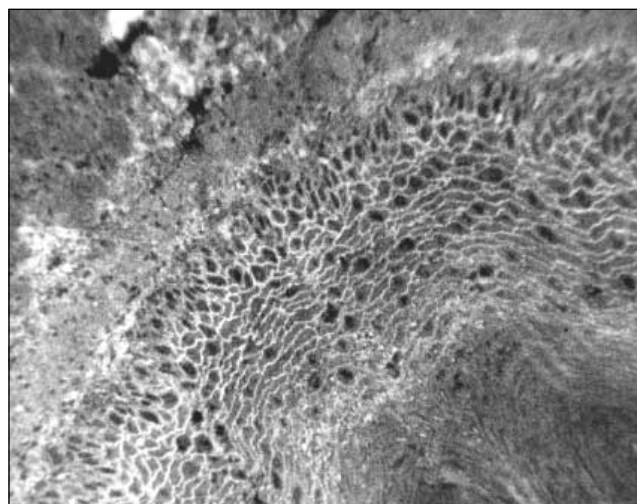


Figure 5  
**Epithelial lining of the oral mucosa: direct immunofluorescence,  
 staining of the intercellular space (polyvalent SwAHu/FITC).  
 Pozitivní přímá imunofluorescence proti mezibuněčnému tmelu  
 a membráně akantolytických keratocytů (polyvalentní  
 SwAHu/FITC).**

antibody levels measured by the ELISA method utilizing recombinant proteins, not by an indirect immunofluorescence test (11). Sera containing anti desmoglein 3 antibodies (IgG) alone cause mucosal dominant pemphigus vulgaris with limited skin involvement while sera containing only anti desmoglein 1 antibodies cause pemphigus foliaceus (2). Autoanti-

body production interferes with intercellular adhesivity and results in intraepithelial blister formation. Biopsy of perilesional tissue, histologic and immunostaining examinations, is essential to the diagnosis. Histologically, there is evidence of intraepithelial acantholysis without disruption of the basement membrane zone. Serum autoantibodies are best detected by indirect immunofluorescence tests (with use of normal human skin, monkey oesophagus and guinea pig as substrates), by enzyme-linked immunosorbent assay (ELISA) (26) or by immunoblotting. The use of drugs is a common cause in drug-induced pemphigus cases. We cannot exclude the possible triggering effect of drugs used by our patient on the progression and unresponsiveness of treatment the disease. However, the most common antiepileptic drugs, which are referred to pemphigus are carbamazepine and valproic acid used temporarily some years ago.

In pemphigus vulgaris the first site of occurrence of the flaccid bullae is the oropharynx and later it can spread to involve the skin. The coincidental involvement of the oesophagus is described sporadically (3,7,12,14). More often we could see it in the mucosal dominant type of pemphigus vulgaris (target antigen is desmoglein 3). However, in an endoscopic study of oesophageal lesions, it was found that seven patients out of eight suffer from oropharyngeal pemphigus vulgaris (10). In another study, upper endoscopy revealed oesophageal involvement in five out of eight patients (18). There are several but not frequent studies dealing with the involvement of oesophagus in pemphigus vulgaris. Oesophageal involvement has rarely been reported, perhaps because it is undetected or misdiagnosed as steroid-induced oesophagitis and/or peptic ulcers and subsequently treated with an inappropriate reduction of the daily steroid use (29). Since 1970 about 58 cases of oesophageal pemphigus have been reported (22). Patterson documented the first oesophageal involvement in pemphigus in 1935 (23). Shirikawa reported in 1998 that, as in the epidermis, the cell adhesion molecule desmoglein 3, the target antigen of pathogenic pemphigus vulgaris autoantibodies, is strongly expressed in stratified squamous epithelia of the oesophagus (28). Upper endoscopy describes many plaque-like lesions with an erythematous base, blisters and erosions or red longitudinal lines (oesophagitis dissecans superficialis) on the oesophageal mucosa. Upper endosco-

py is not a routine method in the investigation of patients with pemphigus vulgaris. Endoscopy is indicated in patients with odynophagia, epigastric pain or bleeding of the gastrointestinal tract. It must be kept in mind that these painful symptoms could be involved because of ulcers caused by side effects of corticosteroids and the diagnosis of oesophageal involvement by primary disease could be disguised (20). Early endoscopy should be performed to avoid inappropriate therapy due to misdiagnosis of suspected steroid-induced oesophagitis or peptic ulcers (22). The examination should be performed by a skilled endoscopist to avoid endoscope-induced Nikolsky sign (dislodgement of intact superficial epidermis/mucosa by a shearing force, indicating a plane of cleavage in the skin/mucosa) (5). By that way, it might be shown that such oesophageal involvement is more widespread than present findings indicate (16).

Oesophageal involvement is relatively uncommon but could exhibit serious consequences. It is most often diagnosed in patients who do not respond to appropriate adjustment to corticosteroid or immunosuppressive therapy (8). It is suggested that endoscopic examination of the oesophageal mucosa is an objective criterion to judge the success of therapy in pemphigus vulgaris (18). The response to systemic and local glucocorticosteroid treatment of our patient was not satisfactory for months, which validates the previous statement. Corticosteroids are the mainstay of treatment for patients with pemphigus vulgaris, with or without other immunosuppressive agents. Treatment should be initiated immediately and continued until there is cessation of new blister formation and Nikolsky sign can no longer be elicited. Dosage is then reduced until all of the lesions have cleared, followed by tapering to a minimum effective maintenance dosage (4). Although therapy reduced the lethality, it may be associated with serious side effects. Plasmapheresis is an effective alternative treatment for patients suffering from pemphigus vulgaris who are not responsive to conventional therapy or these drugs are contraindicated as well as in patients with severe clinical manifestations requiring a high dose of glucocorticosteroids and other immunosuppressants to keep diseases under control (17). Immunoadsorption therapy has become popular for the treatment of various autoimmune diseases as the number of clinically available immunoadsorption columns increases

(21). Protein A immunoadsorption is a rational, effective and safe adjuvant therapy for severe pemphigus and warrants wider use for this indication. It specifically removes immunoglobulin from the circulation, allows treatment of larger plasma volumes, and does not require the substitution of plasma components (27). Immunoadsorption with tryptophan-linked polyvinylalcohol adsorbers also holds promise as a highly effective and safe adjuvant therapeutic regimen in pemphigus (15). Other therapeutic possibilities include the use of mycophenolate mofetil, it seems to be an effective and relatively safe treatment (19). The anti-CD20 monoclonal antibodies have been tried with significant benefit in pemphigus vulgaris therapy (6).

## REFERENCES

- Amagai M, Klaus-Kovtun V, Stanley JR. Autoantibodies against a novel epithelial cadherin in pemphigus vulgaris, a disease of cell adhesion. *Cell* 1991; 67: 869 - 877.
- Amagai M. Autoimmunity against desmosomal cadherins in pemphigus. *J Dermatol Sci* 1999; 20: 92 - 102.
- Amichai B, Grunwald MH, Gasper N, Finkelstein E, Halevy S. A case of pemphigus vulgaris with oesophageal involvement. *J Dermatol* 1996; 23: 214 - 215.
- Bickle KM, Roark TR, Hsu S. Autoimmune bullous dermatoses. *Am Fam Phys* 2002; 65: 1861 - 1870.
- Coelho LK, Troncon LE, Roselino AM. Esophageal Nikolsky's sign in pemphigus vulgaris. *Endoscopy* 1997; 29: S35.
- Cooper HL, Healy E, Theaker JM, Friedmann PS. Treatment of resistant pemphigus vulgaris with an anti-CD 20 monoclonal antibody (rituximab). *Clin Exp Dermatol* 2003; 28: 366 - 368.
- Eliakim R, Goldin E, Livshin R, Okon E. Esophageal involvement in pemphigus vulgaris. *Am J Gastroenterol* 1988; 83: 155 - 157.
- Goldberg NS, Weiss SS. Pemphigus vulgaris of the oesophagus in women. *J Am Acad Dermatol* 1989; 21: 1115 - 1118.
- Goldstein BG, Goldstein AO. Pemphigus and bullous pemphigoid. *UpToDate*. Wellesley, vol. 9.1, 2001, <http://www.uptodate.com>
- Gomi H, Akiyama M, Yakabi K, Nakamura T, Matsuo I. Oesophageal involvement in pemphigus vulgaris. *Lancet* 1999; 354: 1794.
- Harman KE, Seed PT, Gratian MJ, Bhogal BS, Challacombe SJ, Black MM. The severity of cutaneous and oral pemphigus is related to desmoglein 1 and 3 antibody levels. *Br J Dermatol* 2001; 144: 775 - 780.
- Hausermann P, Gutersohn T, Beltraminelli H, Schiller P, Buchner SA, Ruffli T. Oral pemphigus vulgaris successful treatment with minocycline and nicotinamide. *Dermatology* 2002; 53: 813.
- Jullien D. Intravenous immunoglobulin use in dermatology. *Eur J Dermatol* 1997; 7: 471 - 473.
- Kamm MA, Brennan JA, Davies DJ, Desmond PV. Pemphigus of the oesophagus. *Clin Gastroenterol* 1988; 10: 324 - 326.
- Luftl M, Stauber A, Mainka A, Klingel R, Schuler G, Hertl M. Successful treatment of pathogenic autoantibodies in pemphigus by immunoadsorption with a tryptophan-linked polyvinylalcohol adsorber. *Br J Dermatol* 2003; 149: 598 - 605.
- Luire R, Trattner A, David M, Sandbank M. Oesophageal involvement in pemphigus vulgaris: report of two cases and review of the literature. *Dermatologica* 1990; 181: 233 - 236.
- Mazzi G, Raineri A, Zanolli FA, Da Ponte C, De Roia D, Santarossa L, Guerra R, Orazi BM. Plasmapheresis therapy in pemphigus vulgaris and bullous pemphigoid. *Transfus Apheresis Sci* 2003; 28: 13 - 18.
- Mignogna MD, Lo Muzio L, Galloro G, Satriano RA, Ruocco V. Oral pemphigus: clinical significance of oesophageal involvement - report of eight cases. *Oral Surg Oral Med Oral Pathol Oral Radiol Endod* 1997; 84: 179 - 184.
- Mimouni D, Anhalt GJ, Cummins DL, Kouba DJ, Thorne JE, Noursari HC. Treatment of pemphigus vulgaris and pemphigus foliaceus with mycophenolate mofetil. *Arch Dermatol* 2003; 139: 739 - 742.
- Mobacken H, Al Karawi M, Mohamed A, Coode P. Oesophageal pemphigus vulgaris. *Dermatologica* 1988; 176: 266 - 269.
- Nakaji S. Current topics on immunoadsorption therapy. *Ther Apher* 2001; 5: 301 - 305.
- Pallesci GM, Cipollini EM, Lotti T. Development of oesophageal involvement in a subject with pemphigus vulgaris: a case report and review of the literature. *J Eur Acad Dermatol* 2002; 16: 405 - 408.
- Patterson TC. A simple superficial esophageal cast. *J Pathol* 1935; 40: 559 - 569.
- Ruocco E, Aurilia A, Ruocco V. Precautions and suggestions for pemphigus patients. *Dermatology* 2001, 203: 201 - 207.
- Ruocco V, Brenner S, Ruocco E. Pemphigus and diet: does a link exist? *Int J Dermatol* 2001; 40: 161 - 163.
- Scully C, Challacombe SJ. Pemphigus vulgaris: Update on etiopathogenesis, oral manifestations, and management. *Crit Rev Oral Biol Med* 2002; 13: 397 - 408.
- Schmidt E, Klinker E, Opitz A, Herzog S, Sitaru C, Goebeler M, Mansouri Taleghoni B, Brocker EB, Zillikens D. Protein A immunoadsorption: a novel and effective adjuvant treatment of severe pemphigus. *Br J Dermatol* 2003; 148: 1222 - 1229.
- Shirakata Y, Amagai M, Hanakawa Y, Nishikawa T, Hashimoto K. Lack of mucosal involvement in pemphigus foliaceus may be due to low expression of desmoglein 1. *J Invest Dermatol* 1998; 110: 76 - 78.
- Trattner A, Lurie R, Leiser A, David M, Hazaz B, Kadish U, Sandbank M. Esophageal involvement in pemphigus vulgaris: a clinical, histologic, and immunopathologic study. *J Am Acad Dermatol* 1991; 24: 223 - 226.

There are also reports about possible alternative therapy with nicotinamide and minocycline in pemphigus vulgaris (12). This may be a further option for our young patient with a serious form of this potentially lethal disease. High dose intravenous immunoglobulins (0.4 g/kg/day for 5 days) significantly improved biological and clinical activity in refractory forms of pemphigus. Furthermore, i.v. immunoglobulins allowed these other therapeutic agents, notably steroids, to be reduced (13). It seems that upper GI endoscopy is a useful diagnostic method in patients suffering from the mucosal dominant type of pemphigus vulgaris and we believe that it should be a standard diagnostic procedure in these patients.

## Correspondence to / adresa pro korespondenci:

Miroslava Kloudová, MD, Clinical Centre, 2nd Department of Medicine, Charles University Teaching Hospital, Sokolská 581, 500 05 Hradec Králové, Czech Republic  
E-mail: [wirka@email.cz](mailto:wirka@email.cz)