

Pemphigus: crastina sit nescis quid partitura dies

(you do not know what tomorrow will bring)

Miloslav Salavec

The term pemphigus refers to a group of autoimmune intraepidermal blistering diseases of the skin and mucous membranes (10). The acquired diseases of the pemphigus do not heal spontaneously and are primarily characterized by acantholysis within the epidermis leading to blistering (7). The term pemphigus, from the Greek pemphix meaning „bubble“, originated with Hippocrates, who described a pemphigoid fever that was not characterized by blisters and thus probably did not represent pemphigus (12). In 1791 Wichmann gave the name pemphigus to a chronic blistering disease that corresponds to what is today recognized as pemphigus. At the beginning of the last century all blistering diseases were classified under the name pemphigus. First in 1953 Lever (11) characterized pemphigus vulgaris as an entity distinct from bullous pemphigoid. That classification was based upon histopathologic features, clinical aspects and the course of the disease (11). In 1964, Beutner and Jordan demonstrated pemphigus autoantibodies bound to an intercellular substance in skin and mucosal epithelia (5).

Pemphigus occurs in three major forms: pemphigus vulgaris, pemphigus foliaceus and paraneoplastic pemphigus. Other variants have been described in literature. They could be regarded as subtypes of pemphigus vulgaris or the pemphigus foliaceus family (e.g. pemphigus vegetans, pemphigus erythematosus, Brazilian endemic pemphigus (fogo selvagem, endemic variant of pemphigus foliaceus) or drug-induced pemphigus types both in pemphigus vulgaris and pemphigus foliaceus).

Pemphigus is a rare disease. The incidence varies from 0.5 to 3.2 cases per 100,000 people per year (13). Although pemphigus has been reported in all races and ethnic groups, a significantly increased prevalence of the diseases has been observed in the Jewish population (1,15). There is an equal incidence

in males and females. In pemphigus vulgaris the mean age of onset is between 40 and 60 years.

Primary lesion of pemphigus vulgaris is a flaccid blister arising on normal or erythematous skin (Fig. 1). The blisters are fragile and break readily leaving erosions of the skin and mucous membranes. Oral lesions are typical for pemphigus vulgaris and the disease often originates in the oral cavity (in 50 - 70 % of patients). Time lapse could be recorded between the initial oral manifestations of pemphigus vulgaris and the occurrence of skin blisters (10). Involvement of all stratified squamous epithelial mucosa surface may occur and there are reports of pemphigus vulgaris involving the pharynx, larynx, oesophagus, conjunctiva, urethra, vulva, cervix and rectal mucosa (11). Kloudová et al. (9) described such a serious oesophageal involvement in a young female in this issue of the Journal. The disease often becomes generalized and, if left untreated, pemphigus is almost always fatal. The histopathologic hallmark in pemphigus vulgaris is a suprabasal acantholytic blister.

Patients with pemphigus foliaceus rarely have

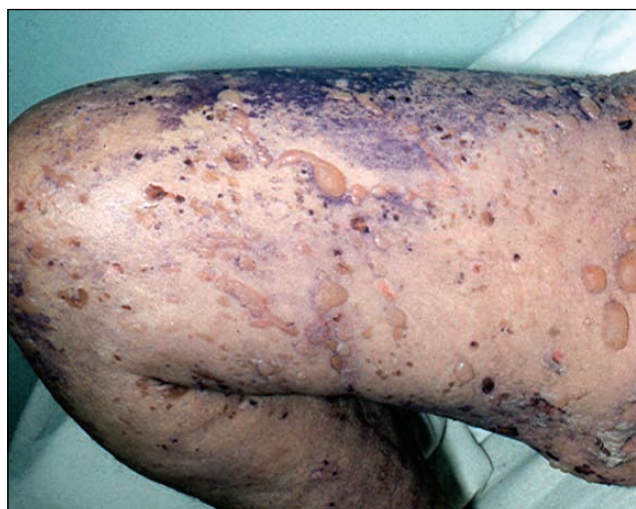

Figure 1
Blisters on the skin in pemphigus vulgaris.

mucosal membrane lesions. Skin lesions are most commonly presented with erythematous patches and erosions covered with crusts on the face, scalp, upper chest, and abdomen but may involve the entire skin (exfoliative erythroderma). Pemphigus foliaceus is a superficial form of pemphigus with acantholysis in the granular layer of the epidermis, bullae hardly ever present.

Paraneoplastic pemphigus is a very rare clinical entity, first described in 1990 by Anhalt and co-workers (4). Female to male ratio is 2:1 with the onset of the disease at 60 years of age and older. It is associated with malignancy, most often lymphoid (leukaemia or lymphoma). Extensive painful mucocutaneous erosions, resembling pemphigus vulgaris are typical but targetoid erythematous papules similar to erythema multiforme may also be present. It is distinguished from the other forms of pemphigus as direct immunofluorescence reveals not only IgG and C3 deposits within the intercellular spaces but also along the basement membrane zone and there is staining of other tissues, including the bladder, heart and liver (6).

Autoantibodies play a major pathogenic role in pemphigus diseases. Pemphigus is a disease of cell-cell adhesion caused by circulating autoantibodies. Findings indicate that autoantigens for both pemphigus vulgaris and pemphigus foliaceus are members of the desmoglein subfamily in the cadherin supergene family (2). Desmogleins are transmembrane glycoprotein components of the core region of desmosomes, cell adhesion junctions typical of stratified squamous epithelia. Immunochemical studies with pemphigus foliaceus autoantibodies and molecular cloning studies with pemphigus vulgaris autoantibodies identified desmogleins (Dsg) as target antigens in pemphigus group (14). Patients with pemphigus foliaceus have antibodies reactive with only Dsg 1, while patients with pemphigus vulgaris have antibodies against Dsg 3 and in some patients also antibodies against Dsg 1 (mucocutaneous type) are detectable. In some pemphigus vulgaris patients, sera containing anti-Dsg 3 alone cause mucosal dominant pemphigus vulgaris with limited skin involvement (3). Early in the course of pemphigus vulgaris (mucous membranes involvement) patients tend to only have antibodies against Dsg 3. Anti-Dsg 1 antibodies are produced later in the diseases with the consequent involvement of the skin (8). Serum levels of circulating autoantibodies correlate directly with diseases activity. Patients

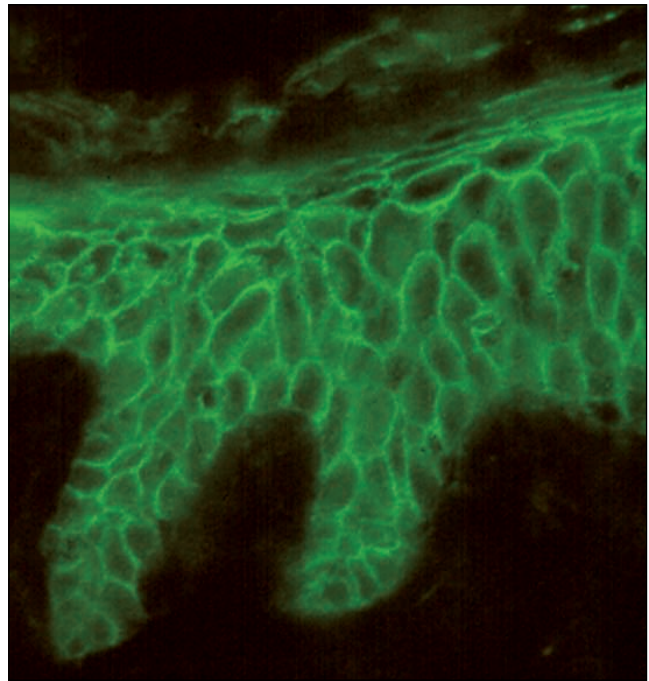


Figure 2
Positive direct immunofluorescence intraepidermal IgG deposits in the intercellular substance (SWAHu IgG).

with paraneoplastic pemphigus have autoantibodies against multiple molecules (the so-called plakin family) and cell surface target antigens of paraneoplastic pemphigus, which blister-inducing pathogenic autoantibodies attack, were finally discovered to be Dsg 3 and Dsg 1. Therefore paraneoplastic pemphigus is characterized as an autoimmune disease against plakin molecules and desmogleins (3).

Diagnosis of pemphigus diseases is based on biopsy of perilesional tissue, with histological and immunohistochemical examinations (Fig. 2). Serum circulating autoantibodies are detected by indirect immunofluorescence tests or by enzyme-linked immunosorbent assay (ELISA).

Treatment modalities are largely based on systemic immunosuppression using systemic corticosteroids. They constitute the mainstay of efficacious therapeutic regimen. Before corticosteroid introduction, pemphigus was invariably fatal. Unfortunately, paraneoplastic pemphigus is relatively unresponsive to corticosteroids or other regimens. Pulse corticosteroid treatment has also been advocated (14). Other immunosuppressive drugs are used as steroid-sparing agents, especially in patients who are at risk from osteoporosis and other steroid-induced adverse effects. Azathioprine and cyclophosphamide have been used as well as parenteral gold, dapsone, cyc-

losporine, intravenous human immunoglobulin and mycophenolate mofetil. Plasmapheresis and immuno-adsorption methods could be beneficial in patients with refractory disease.

Research in dermatology (immunodermatology) leading to an understanding of the mechanisms of autoantibodies formation may implement a more specific intervention. By identification of epitopes recognized by T cells in pemphigus patients we could develop antagonist, anergizing peptides. Cytokines, their agonist and antagonist redirecting T cell responses may prove to be useful (14).

Regarding all clinical aspects of various forms of the pemphigus group, we would like to emphasize the need for interdisciplinary co-operation (dermatology, immunology, gastroenterology and oral medicine) in diagnosing and implementing specific, the most effective management of such serious diseases.

REFERENCES

- Ahmed AR, Sofen H. Familial occurrence of pemphigus vulgaris. *Arch Dermatol* 1982; 118: 423 - 424.
- Amagai M. Adhesion molecules. I: Keratinocyte-keratinocyte interactions; Cadherins and pemphigus. *J Invest Dermatol* 1995; 104: 146 - 152.
- Amagai M. Autoimmunity against desmosomal cadherins in pemphigus. *J Dermatol Science* 1999; 20: 92 - 102.
- Anhalt GJ, SooChan K, Stanley JR, Korman NJ, Jabs DA, Kory M, Izumi H, Ratrie H, Mutasim D, Ariss-Abdo L, Labib RS. Paraneoplastic pemphigus, an autoimmune mucocutaneous disease associated with neoplasia. *N Engl J Med* 1990; 323: 1729 - 1735.
- Beutner EH, Jordan RE. Demonstration of skin antibodies in sera of pemphigus vulgaris patients by indirect immunofluorescent staining. *Proc Soc Exp Biol Med* 1964; 117: 505 - 510.
- Bickle KM, Roark TR, Hsu S. Autoimmune bullous dermatoses: a review. *Am Fam Phys* 2002; 65: 1861 - 1870.
- Braun-Falco O, Plewig G, Wolff HH, Winkelmann RK. *Dermatology*. Berlin: Springer Verlag, 1991, 474.
- Ding X, Aoki V, Mascaro JM, Lopez-Swidorski A, Diaz LA, Fairley JA. Mucosal and mucocutaneous (generalized) pemphigus vulgaris show distinct antibody profiles. *J Invest Dermatol* 1997; 109: 592 - 596.
- Kloudová M, Kopáčová M, Slezák R, Salavec M, Nožička Z, Rejchrt S, Bureš J. Serious oesophageal involvement in a young female patient with pemphigus vulgaris. *Folia Gastroenterol Hepatol* 2004; 2: 133 - 138.
- Korman N. Pemphigus. Continuing medical education. *J Am Acad Dermatol* 1988; 18: 1219 - 1238.
- Lever WF. Pemphigus. *Medicine* 1953; 32: 1 - 123.
- Lever WF, Talbott JH. Pemphigus. A clinical analysis and follow-up study of sixty-two patients. *Arch Dermatol* 1942; 46: 348 - 357.
- Lynch P, Gallego RE, Saied NK. Pemphigus - a review. *Arisona Med* 1976; 33: 1030 - 1037.
- Udey MC, Stanley JR. Pemphigus - diseases of antidesmosomal autoimmunity. *J Am Med Assoc* 1999; 282: 572 - 576.
- Voelter WW, Newell GB, Schwartz CL, Bean SF, Mullins JF. Familial occurrence of pemphigus foliaceus. *Arch Dermatol* 1973; 108: 93 - 94.

Correspondence to:

Miloslav Salavec, MD, PhD, Department of Dermatology, Charles University Teaching Hospital, Hradec Králové, Czech Republic
E-mail: salavecm@post.cz