

# Pneumatosis cystoides intestinalis

## A case report and review of the literature

Jiří Cyrano<sup>1</sup>, Marcela Kopáčová<sup>1</sup>, Helena Hornychová<sup>2</sup>, Aleš Ryška<sup>2</sup>, Stanislav Rejchrt<sup>1</sup>, Jan Bureš<sup>1</sup>

<sup>1</sup> 2nd Department of Medicine, Charles University in Prague, Faculty of Medicine at Hradec Králové, University Teaching Hospital, Hradec Králové, Czech Republic

<sup>2</sup> The Fingerland Department of Pathology, Charles University in Prague, Faculty of Medicine at Hradec Králové, University Teaching Hospital, Hradec Králové, Czech Republic

Cyrano J, Kopáčová M, Hornychová H, Ryška A, Rejchrt S, Bureš J. *Pneumatosis cystoides intestinalis. A case report and review of the literature. Folia Gastroenterol Hepatol 2005; 3 (2): 68 – 73.*

**Abstract.** A case of an incidental endoscopic finding of pneumatosis cystoides intestinalis in the large bowel is presented. Diagnosis was verified by fine needle aspiration cytology. Basic facts about this uncommon entity are reviewed with an emphasis on endoscopic differential diagnosis.

**Key words:** pneumatosis cystoides intestinalis, colorectal polyp, pneumoperitoneum

Cyrano J, Kopáčová M, Hornychová H, Ryška A, Rejchrt S, Bureš J. *Pneumatosis cystoides intestinalis. Kazuistika a přehled literatury. Folia Gastroenterol Hepatol 2005; 3 (2): 68 – 73.*

**Souhrn.** Prezentujeme případ náhodného endoskopického nálezu pneumatosis cystoides intestinalis v tlustém střevě, verifikovaný tenkojehlovou aspirační cytologií. Předkládáme přehled základních faktů o této neobvyklé jednotce s důrazem na endoskopickou diferenciální diagnostiku.

**Klíčová slova:** pneumatosis cystoides intestinalis, kolorektální polyp, pneumoperitoneum

Pneumatosis cystoides intestinalis is a rare gastrointestinal condition, in the majority of cases an incidental finding which represents a differential diagnostic challenge for endoscopist, radiologist, pathologist and physician.

### Case report

A 51-year-old man underwent colonoscopy elsewhere for diarrhoea and slight haematochezia and he was then referred to our endoscopy unit for supervision because of finding several polyps in the hepatic flexure region. During colonoscopy we found several sessile polyps clustered in streaks, covered with normal mucosa, quite firm on probe palpation (Fig 1 and 2). Biopsy attempts just unroofed normal mucosa away, but polyps disappeared during the puncture and suction with a cytology needle. This typical endoscopic picture led us to suspicion of pneumatosis cystoides intestinalis. Material aspirated from cysts was smeared on cytology glass. Microscopically, two

cell populations were visible – epithelial cells of colonic mucosa, arranged in a honeycomb pattern and numerous multinucleated giant cells of foreign body type (Fig 3) and this confirmed our suspicion. The patient was symptom-free at that time, no pathology was found on abdominal plain X-ray.

### Discussion

Pneumatosis cystoides intestinalis is a rare condition characterized by the presence of gas-filled pseudocysts in the wall of gastrointestinal tract. This condition can be combined with the presence of gas in omentum, mesentery, peritoneal cavity, retroperitoneum and portal venous system (2, 6, 25, 28). The first cases of pneumatosis cystoides intestinalis were described by DuVernoi in the 18th century in post-mortem studies (cited from ref. 27).

Aetiology and pathogenesis of pneumatosis cystoides intestinalis are not clearly known – intraluminal pressure, bacterial flora, intraluminal gas and muco-

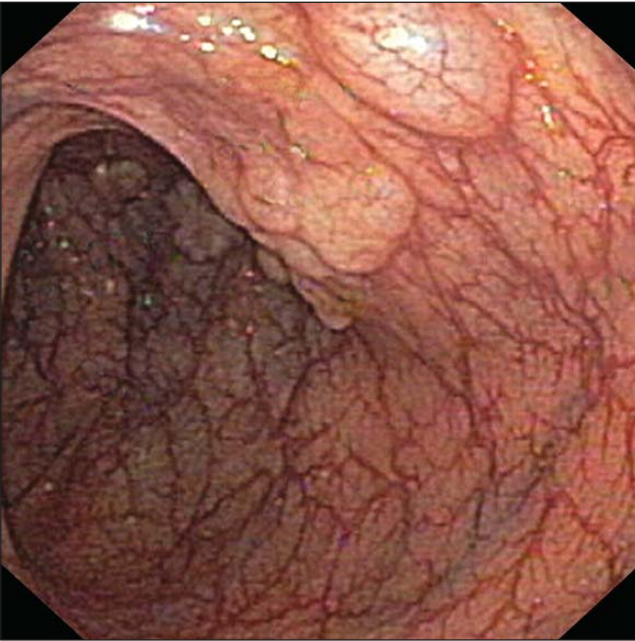


Figure 1 / Obr. 1

Colonoscopy. Several sessile ball-shaped polyps covered with normal mucosa with adequate vascular pattern.  
Koloskopie. Několik přisedlých polokulovitých polypů krytých normální sliznicí s přiměřenou cévní kresbou.

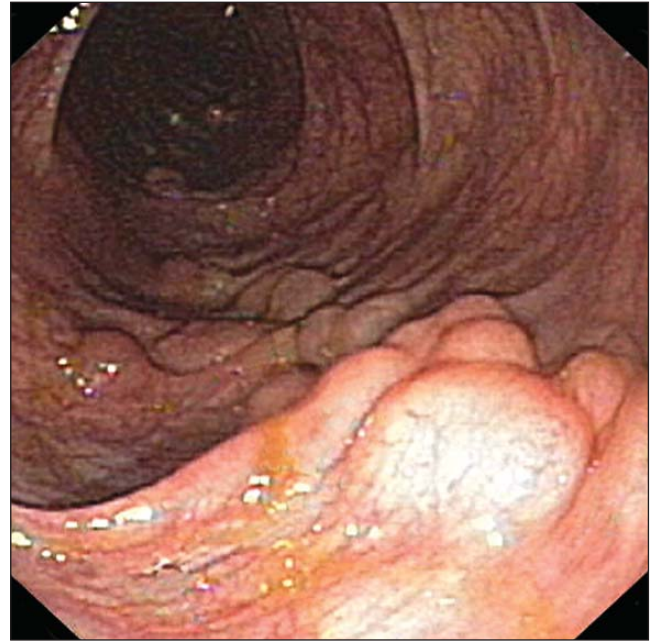


Figure 2 / Obr. 2

Colonoscopy. Sessile ball-shaped polyps clustered in streak in the hepatic flexure region.  
Koloskopie. Přisedlé polokulovité polypy uspořádané do pruhu v oblasti jaterního ohbí.

sal integrity – these factors form this entity (25) to various extents. From an aetiological but also clinical point of view pneumatosis cystoides intestinalis represents inhomogenous phenomenon rather than consistent clinical diagnosis, it is subject to variability of the underlying disease and dominant aetiopathogenetic mechanism. Historically, we can distinguish between primary (idiopathic) (15 %) and secondary pneumatosis cystoides intestinalis, associated with a wide range of diseases (Table 1) with various pathogenetic mechanisms (1, 2, 5, 6, 8, 12, 25, 26, 28). **Traumatic and mechanical factors** lead to pneumatosis cystoides intestinalis through elevation of intraluminal pressure, impairment of mucosal integrity or both. **Inflammatory and connective tissue diseases** as well as **drugs** can destruct mucosal and immune barriers and disturb gut motility. Invasive **microorganisms** can also break the mucosal barrier and

produce gas within the intestinal wall. Non-invasive bacteria forming the normal gut flora play a major role in the genesis of pneumatosis cystoides intestinalis in the large bowel (or in the small bowel in the case of the bacterial overgrowth syndrome). Dispro-

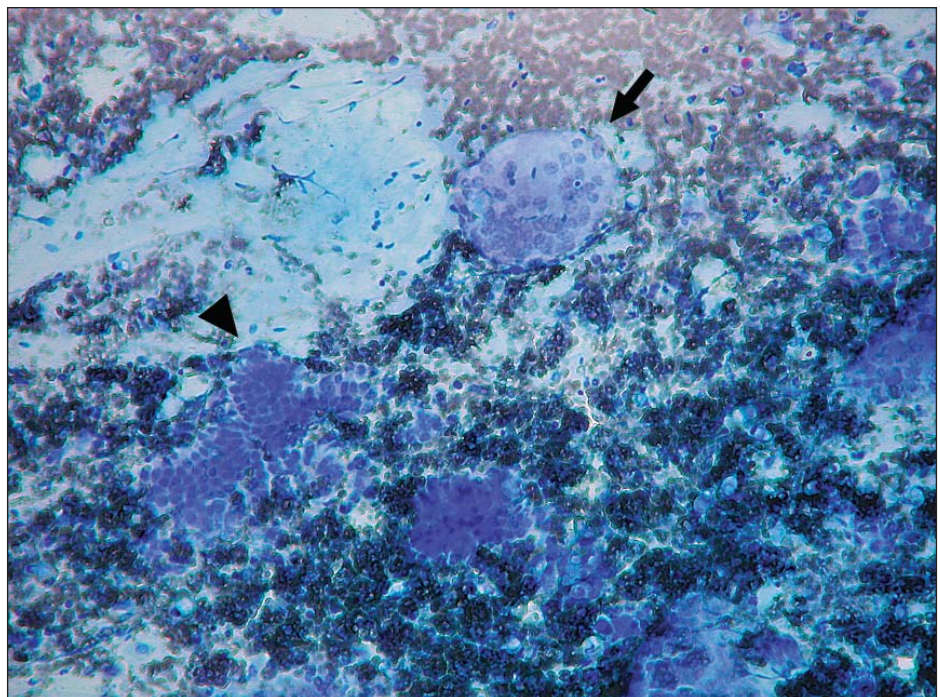


Figure 3 / Obr. 3

Cytology. Multinucleated giant cell (arrow) and aggregate of cylindrical colonic cells (arrowhead) with erythrocytes and mucus on the background (May-Grünwald Giemsa staining, 100-times magnification).

Cytologie. Mnohoaderná buňka (šipka) a shluk cylindrických kolonických buněk (hrot šipky) s erythrocyty a hlenem na pozadí (barvení dle May-Grünwalda Giemsy, zvětšení x100).

Table 1 / Tab. 1

**Underlying conditions of pneumatosis cystoides intestinalis.**  
**Stavy provázené pneumatosis cystoides intestinalis.**

Traumatical and mechanical	Inflammatory and autoimmune	Infectious	Pulmonary	Drug induced	Other
Blunt abdominal trauma	Ulcerative colitis	<i>Clostridium difficile</i>	Asthma bronchiale	Cytotoxic agents	Intestinal infarction
Endoscopy	Crohn's disease	Acquired immunodeficiency syndrome	Chronic obstructive pulmonary disease	Immunosuppression	Necrotising enterocolitis
Jejunioileal bypass	Appendicitis	<i>Cryptosporidium</i>	Artificial ventilation	Corticosteroids	Sarcoidosis
Gastroduodenal ulcer	Diverticular disease	Cytomegalovirus		Lactulose	Multiple sclerosis
Pyloric stenosis	Ruptured Meckel's diverticulum	Rotavirus		alpha-Glucosidase inhibitor	Hirschsprung disease
Duodenal stenosis	Cholelithiasis	Adenovirus		Sorbitol	Primary immunodeficiency
Malrotation	Celiac sprue	Varicella-zoster virus		Practolol	Graft-versus-host disease
Volvulus	Necrotising enterocolitis	<i>Candida albicans</i>		Nitrous oxide	Quadriplegia
Surgical bowel anastomosis		<i>Klebsiella</i>		Trichloroethylene	Pseudoobstruction
Enteric tube placement	Systemic lupus erythematoses	<i>Lactobacillus</i>		Chloral hydrate	Hemodialysis
Needle jejunostomy	Polymyositis	<i>Mycobacterium tuberculosis</i>		Nonsteroidal anti-inflammatory drugs	Cholangiocarcinoma
Intussusception	Dermatomyositis	Whipple's disease			Cystic fibrosis
Carcinoma	Polyarteritis nodosa				Diabetic enteropathy
Barium enema	Scleroderma				Leukemia
Caustic ingestion	Rheumatoid arthritis				Hodgkin's disease
	Sjögren's syndrome				Amyloidosis
	Mixed connective tissue disease				
					<b>Idiopathic (primary)</b>

Modified from 2, 6, 8, 25, 28

portion of hydrogen producing and hydrogen consuming (methanogenic and sulphate-reducing) bacteria and/or presence of nonabsorbed (e.g. lactulose) (7) or malabsorbed (e.g. lactose) substrates leads to intraluminal overproduction of hydrogen, which diffuses into the gut wall followed by nitrogen, oxygen and carbon dioxide diffusing from the blood (4, 15). In **pulmonary disease** fluctuation of intra-abdominal pressure and hypoxia are suggested mechanisms rather than direct diffusion of air from ruptured alveoli through mediastinum, retroperitoneum and mesenterium (25). Rupture of subserosal pseudocysts can lead in about 30 % of cases to pneumoperitoneum without signs of peritonitis or to pneumoretroperitoneum (11, 14, 18, 27). Gas can penetrate to the portal venous system and is considered to be an omi-

nous sign most often associated with intestinal ischemia (20, 21).

Submucosal or subserosal pseudocysts are filled with gas with a high hydrogen content under pressure higher than intraluminal (6). They are from a few millimetres to several centimetres in diameter and form isolated or clustered sessile polyps. The colon is often involved in segments, predominantly the left side (80 % sigmoid, 50 % descending, 40 % transverse colon) than the right side, rarely the rectum (7). Primary pneumatosis cystoides intestinalis more often involves the large intestine, while the small bowel is usually involved in secondary form. Irrespective of the term itself, the stomach and oesophagus can also be affected. Polyps have a honeycombed appearance on the section, without any communication of intramural

Table 2 / Tab. 2

**Differential diagnosis of colorectal polyps.****Diferenciální diagnostika kolorektálních polypů.**

mucosal lesions	neoplastic	adenoma
		carcinoma
	non-neoplastic	hyperplastic (metaplastic) polyp
		juvenile (retention) polyp
		Peutz-Jeghers polyp
		inflammatory polyp
		normal epithelium (mucosal autoplasty)
submucosal lesions	colitis cystica profunda	
	pneumatosis cystoides intestinalis	
	lymphoid polyp	
	lipoma	
	carcinoid	
	metastasis	
Modified from (9)		

spaces with bowel lumen. Microscopically spaces are lined by plump cells of presumably histiocytic origin; they frequently fuse and form multinucleated giant cells. Inflammatory and fibrotic changes in surrounding connective tissue and inflammation in epithelium can rarely develop (6).

Pneumatosis cystoides intestinalis is a very uncommon condition but epidemiological data has evolved during the second half of the 20th century, the incidence has been increasing (partially because of expansion of cross-sectional imaging) and the spectrum of underlying conditions is changing (from gastroduodenal ulcer in 1950 to steroids and chemotherapy in 1990) (2). Pneumatosis cystoides intestinalis in adults can appear at any age with peak occurrence between 30 to 50 years of age. Some sources note a male predominance (7) and there is no racial predominance. Symptoms can be related to underlying disease, the majority of patients are asymptomatic, but several symptoms can be associated with pneumatosis cystoides intestinalis itself: diarrhoea, rectal bleeding, lower abdominal pain, constipation, weight loss, mucoid discharge, bloating and flatulence. Rarely, huge cysts can jam the lumen and cause obstruction, intussusception or volvulus.

**Physical examination** is rarely significant; sometimes we can palpate rectal or abdominal masses. In

Table 3 / Tab. 3

**Differential diagnosis of pneumoperitoneum.****Diferenciální diagnostika pneumoperitonea.**

asymptomatic	pneumatosis cystoides intestinalis
	small bowel diverticulosis
	peritoneal dialysis
	post laparotomy/laparoscopy
	gynaecological source
	mechanical ventilation
	status epilepticus
	etc.
with signs of peritonitis	hollow organ perforation
	penetrating abdominal injury
	peritonitis caused by gas-producing bacteria, rupture of absces
pseudoperitoneum	Chilaiditi sign
	subdiaphragmatic absces
	basal lung plate atelectasis
	etc.
Modified from (11, 14, 17, 27).	

the case of pneumoperitoneum one can find clinical signs of free abdominal air (tympanic percussion, absence of liver dullness) (6). On **endoscopy** several sessile polyps are seen, millimetres to centimetres in diameter, isolated or clustered, often pale or bluish, covered with normal mucosa. One can feel the “cushion-like” consistency of the cyst under mucosa during probe palpation (3, 5, 19, 21, 24). Cysts promptly collapse after cyst wall destruction with larger biopsy forceps or puncture needle. The content of the pseudocysts can be aspirated and used for cytologic examination. For histology it is necessary to obtain a sample including the inner cyst wall with larger biopsy forceps. **Histological samples** show empty spaces lined by multinucleated giant cells as mentioned above. Any attempts to remove polyps by polypectomy should be strictly avoided, otherwise perforation can occur. **Endoscopic ultrasound** can show a strong echo with distal acoustic shadowing in the third layer, representing gas in the submucosa (23). All signs mentioned can help us to distinguish this entity from other types of colorectal polyps (Table 2). Colitis cystica profunda has another cause and usually involves the rectum. **Plain radiographs** (positive in two thirds of cases) show localized gas collection represented by radiolucency

within the gut wall, possibly in the mesenterium or portal vein. Cystic, microvesicular or diffuse pattern can be differentiated. Asymptomatic pneumoperitoneum and pneumoretroperitoneum complicating pneumatosis cystoides intestinalis can be a differential diagnostic challenge especially versus perforation of hollow viscus (Table 3) (14, 18, 27). Gas in the portal venous system can be mentioned in severe cases. **Barium radiographic examination** shows smooth radiolucent defects in barium filling. **Ultrasonography** can show bright echoes with acoustic shadowing, representing gas in the gut wall. Gas in the portal venous system is seen as numerous small hyperechogenic images with inconstant acoustic shadows and has to be differentiated from air in the biliary tract. **Abdominal computerized tomography** is the most sensitive method for detection of pneumatosis cystoides intestinalis and its complications. The large bowel can be prepared with an air-enema, computerized tomography scans should also be evaluated in lung window settings. Intramural gas collections must be differentiated from intraluminal air mixed with stool and submucosal fat. More costly and less sensitive and specific **magnetic resonance imaging** reveals a low signal on T1- and T2-weighted images with more prominence on gradient echo images due to the “blooming” caused by magnetic field inhomogeneities created at air-tissue interfaces (2). **Laparoscopy** reveals multiple, glistening, translucent, pale-bluish subserosal cysts which can rupture on palpation and must be distinguished from arteficial changes associated with carbon dioxide insufflation (17). High H<sub>2</sub> content in alveolar air measured during **breath test** represents supposed pathogenetic mechanism (4, 15).

As mentioned above, the majority of patients (such as our patient) have no complaints and our role is to differentiate other causes of our findings and avoid any invasive treatment (like endoscopic polypectomy, laparotomy for asymptomatic pneumoperitoneum or unnecessary bowel resection). Pneumatosis cystoides intestinalis can also regress spontaneously (10). On the other hand a significant number of patients suffer from persistent symptoms. In the case of secondary form, the underlying disease should be treated first. Elimination of unabsorbed or malabsorbed saccharides – lactulose, sorbitol, xylitol, lactose (in the case of lactase deficiency) and sometimes also elemental diet can help to cyst resolution –

the goal is to eliminate the substrate for bacterial H<sub>2</sub> overproduction (6). A mainstay in medical treatment is oxygen inhalation, which causes reduction of partial pressures of other gases than oxygen (predominantly nitrogen) in the blood, which leads to reverse diffusion of gases from pseudocysts. Oxygen in high partial pressure can also kill gas forming bacteria. It is necessary to reach partial pressure of oxygen around 33 kPa (250 mmHg), oxygen is delivered either under atmospheric pressure (mixture with at least 60% oxygen content by nasal catheter, face mask or tent several hours a day for several days in different schemes) or by hyperbaric oxygenation (200 kPa, up to two hours a day for several days in different schemes) (2,6,16,25,28). Antibiotics (metronidazole, ampicillin, ciprofloxacin) can be used on an outpatient basis for up to several months (2). Successful treatments with infliximab and octreotide are also reported in patients with connective tissue diseases (12, 22).

Endoscopy treatment (polypectomy) should generally be avoided, as mentioned above. Endoscopic puncture of pseudocysts in combination with consecutive conservative treatment in patient with obstructive pneumatosis cystoides intestinalis with high operative risk seems to be an acceptable alternative, but in our opinion, combination with sclerotherapy described (10) carries a high risk of severe complications.

The surgeon should leave his arms at rest in most cases, including the pneumoperitoneum without signs of peritonitis. On the other hand surgical intervention has to be considered in case of the following: severe underlying disease (especially ischaemic bowel), presence of gas in the portal venous system (associated with 37% mortality), obstructive complications, necrosis, perforation with signs of peritonitis and sepsis (2). One must consider that signs of the disease can be modified by corticosteroids and immunosuppressants taken by a lot of affected persons.

In summary, pneumatosis cystoides intestinalis is an uncommon phenomenon with unclear multifactorial aetiology and pathogenesis, which in the secondary form can be associated with a wide spectrum of underlying diseases. In the majority of cases (like in our case report) one can face this condition incidentally on endoscopy or plain abdominal X-ray. Cytology was found to be an effective method for diagnosis in our case. Computerized tomography scan is the

most sensitive method for diagnosis. Reliable differential diagnosis can help to avoid unnecessary invasive treatment. In the other group of patients we have

to recognize the severity of underlying disease and potential complications and consider surgical intervention.

## REFERENCES

- Alcocer-Gouyonnet F, Chan-Nunez C, Hernandez J, Guzman J, Gamboa-Dominguez A. Acute abdomen and lupus enteritis: thrombocytopenia and pneumatosis intestinalis as indicators for surgery. *Am Surg* 2000; 66: 193 – 195.
- Boerner RM, Fried DB, Warshauer DM, Isaacs K. Pneumatosis intestinalis. Two case reports and a retrospective review of the literature from 1985 to 1995. *Dig Dis Sci* 1996; 41: 2272 – 2285.
- Breitinger A, Kozarek R, Hauptman E. Pneumatosis cystoides intestinalis in Crohn's disease. *Gastrointest Endosc* 2003; 57: 241.
- Christl SU, Gibson GR, Murgatroyd PR, Schepach W, Cummings JH. Impaired hydrogen metabolism in pneumatosis cystoides intestinalis. *Gastroenterology* 1993; 104: 392 – 397.
- Chuan CC, Isomoto H, Mizuta Y, Nakazawa M, Murata I, Kohno S. Pneumatosis cystoides intestinalis. *Gastrointest Endosc* 2003; 58: 418.
- Davila AD, Willenbucher RF. Pneumatosis cystoides intestinalis (p 1979 – 1982). In: Sleisenger and Fordtran's *Gastrointestinal and Liver Diseases*. M Feldman, BF Scharschmidt, MH Sleisenger, eds. 6th Ed. Philadelphia: WB Saunders, 1998.
- Goodman RA, Riley TR 3rd. Lactulose-induced pneumatosis intestinalis and pneumoperitoneum. *Dig Dis Sci* 2001; 46: 2549 – 2553.
- Goyal SK. Pneumatosis intestinalis. <http://www.emedicine.com/radio/topic560.htm>
- Itzkowitz SH, Kim YS. Colonic polyps and polyposis syndrome (p 1866). In: Sleisenger and Fordtran's *Gastrointestinal and Liver Diseases*. M Feldman, BF Scharschmidt, MH Sleisenger, eds. 6th Ed. Philadelphia: WB Saunders, 1998.
- Johansson K, Lindstrom E. Treatment of obstructive pneumatosis coli with endoscopic sclerotherapy: report of a case. *Dis Colon Rectum* 1991; 34: 94 – 96.
- Khan AN. Pneumoperitoneum. <http://www.emedicine.com/radio/topic562.htm>.
- Kobayashi T, Kobayashi M, Naka M, Nakajima K, Momose A, Toi M. Response to octreotide of intestinal pseudoobstruction and pneumatosis cystoides intestinalis associated with progressive systemic sclerosis. *Intern Med* 1993; 32: 607 – 609.
- Kreiss C, Forohar F, Smithline AE, Brandt LJ. Pneumatosis intestinalis complicating *C. difficile* pseudomembranous colitis. *Am J Gastroenterol* 1999; 94: 2560 – 2561.
- Krejs GJ. Free abdominal and/or retroperitoneal air. Clinical aspects (p 93 – 97). In: *New developments in the management of benign GI disorders*. DJ Gouma, GJ Krejs, GN Tytgat, Y Finkel, eds. Paris: John Libbey Eurotext, 2004.
- Levitt MD, Olsson S. Pneumatosis cystoides intestinalis and high breath H<sub>2</sub> excretion: Insights into the role of H<sub>2</sub> in this condition. *Gastroenterology* 1995; 108: 1560 – 1565.
- Lustberg AM, Fantry GT, Cotto-Cumba C, Drachenberg C, Darwin PE. Hyperbaric oxygen treatment for intractable diarrhea caused by pneumatosis coli. *Gastrointest Endosc* 2002; 56: 935 – 937.
- Mehta SN, Friedman D, Fried GM, Mayrand S. Pneumatosis cystoides intestinalis: laparoscopic features. *Am J Gastroenterol* 1996; 91: 2610 – 2612.
- Myre LE, Pinon S, Forman WB. Causes of benign asymptomatic pneumoperitoneum. *Am Fam Physician* 2004; 69: 29 – 32.
- Neiblum DR. Primary pneumatosis cystoides intestinalis. *Gastrointest Endosc* 2001; 53: 404.
- Peloponissios N, Halkic N, Pugnale M, Jornod P, Nordback P, Meaer A, Gillet M. Hepatic portal gas in adults: review of the literature and presentation of a consecutive series of 11 cases. *Arch Surg* 2003; 138: 1367 – 1370.
- See C, Elliott D. Images in clinical medicine. Pneumatosis intestinalis and portal venous gas. *N Engl J Med* 2004; 350: e3.
- Selva-O'Callaghan, Martinez-Costa X, Solans-Laque R, Mauri M, Capdevila JA, Vilardell-Tarres M. Refractory adult dermatomyositis with pneumatosis cystoides intestinalis treated with infliximab. *Rheumatology (Oxford)* 2004; 43: 1196 – 1197.
- Shimada M, Ina K, Takahashi H, Horiuchi Y, Imada A, Nishio Y, Ando T, Kusugami K. Pneumatosis cystoides intestinalis treated with hyperbaric oxygen therapy: usefulness of an endoscopic ultrasonic catheter probe for diagnosis. *Intern Med* 2001; 40: 896 – 900.
- Stollman NH, Lee KF. Primary pneumatosis cystoides intestinalis. *Gastrointest Endosc* 2000; 52: 233.
- St Peter SD, Abbas MA, Kelly KA. The spectrum of pneumatosis intestinalis. *Arch Surg* 2003; 138: 68 – 75.
- Terzic A, Holzinger F, Klaiber C. Pneumatosis cystoides intestinalis as a complication of celiac disease. *Surg Endosc* 2001; 15: 1360 – 1361.
- Theisen J, Juhnke P, Stein HJ, Siewert JR. Pneumatosis cystoides intestinalis coli. A rare differential diagnosis of pneumoperitoneum. *Surg Endosc* 2003; 17: 157 – 158.
- Vobořil R. Pneumatosis cystoides intestinalis – a review. *Acta Medica (Hradec Králové)* 2001; 44: 88 – 92.

### Correspondence to / adresa pro korespondenci:

Jiří Cyrany, MD, 2nd Department of Medicine,  
Charles University Teaching Hospital,  
Sokolská 581, 500 05 Hradec Králové, Czech Republic  
E-mail: jiri.cyrany@email.cz