

Pancreatic serous cystadenoma mimicking invasive cystadenocarcinoma

Marek Hartleb¹, Wojciech Wawrzynek², Anatol Wodołański³, Andrzej Nowak¹, Paweł Lampe⁴

¹ Department of Gastroenterology, Silesian Medical School, Katowice, Poland

² Department of Radiology, Silesian Medical School, Katowice, Poland

³ Department of Pathomorphology, Silesian Medical School, Katowice, Poland

⁴ Department of Gastrointestinal Surgery, Silesian Medical School, Katowice, Poland

Hartleb M, Wawrzynek W, Wodołański A, Nowak A, Lampe P. Pancreatic serous cystadenoma mimicking invasive cystadenocarcinoma. *Folia Gastroenterol Hepatol* 2006; 4 (1): 27 – 29.

Abstract. We report a 54-year-old female with a CT image of a 6x4 cm multiloculated pancreatic mass, invading the posterior wall of the stomach. At radiofluoroscopy the mid portion of the stomach was hypokinetic and narrowed, and at gastroscopy the mucosal folds in the corresponding area were rigid. Therefore, radiological methods strongly suggested the diagnosis of locally advanced cystadenocarcinoma. After surgery, pathomorphological examination showed marked peritumoural inflammation, and the cysts were lined by cuboidal, non-motopic epithelium, not producing mucus. This is an unusual case of oligocystic variant of serous cystadenoma imitating invasive cystadenocarcinoma.

Key words: pancreatic cyst, cystadenoma serous, oligocystic variant

The major challenge in the diagnosis of cystic pancreatic lesions involves distinguishing among a postinflammatory pseudocyst, serous cystadenoma, mucinous cystadenoma/cystadenocarcinoma, intraductal papillary mucinous neoplasia and endocrine tumour with cystic degeneration (2). We report a case of pancreatic serous cystadenoma mimicking both, clinically and on imaging findings, locally advanced cystadenocarcinoma.

Case report

A 54-year-old woman was evaluated for intermittent epigastric discomfort, which had caused a reduction of her dietary intake, leading to 3 kg loss of weight. Ultrasonography and helical computerized tomography (CT) showed a 6x4 cm multiloculated cystic mass involving the head of the pancreas and invading the stomach (Fig. 1). Besides, there was a punctuate calcification in the central part of the tumour (visible also on precontrast scans). There were no mural nodules or papillary projections inside the cysts. The patient refused fine needle aspiration

biopsy of the tumour. Her past medical history included arterial hypertension and gastric ulcer, but no acute or chronic pancreatitis. Physical examination was essentially unrevealing and routine laboratory investigations, including tumour markers CEA and CA19-9, were normal. At radiofluoroscopy the mid portion of the stomach was hypokinetic and narrowed suggesting a malignancy (Fig. 2). The upper gastrointestinal endoscopy showed thickened and rigid mucosal folds on the posterior area of gastric body, however, multiple forceps biopsies failed to prove neoplasia. According to large size of the cysts and extension of the tumour into the stomach, our preoperative diagnosis was locally advanced cystadenocarcinoma. Laparotomy confirmed pancreatic cystic mass being in direct continuation with the posterior surface of the stomach and showing significant peritumoural inflammation. On surgical inspection the antrum was hard and stiff, like in “linitis plastica”. Surgical resection of the tumour with pancreaticojejunostomy were performed. There was no real ingrowth of the pancreatic tumour into the gastric

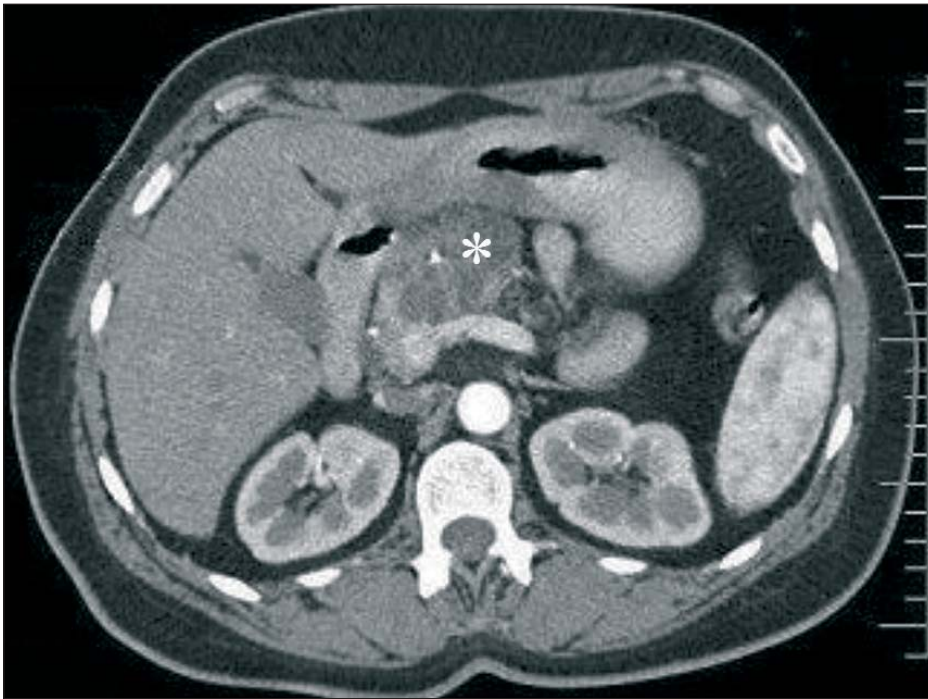


Figure 1
CT shows a large, multiloculated cyst (asterisk) involving the head of the pancreas. The cystic mass extends to the posterior gastric wall. Besides, there is a punctate calcification in the central part of the tumour.

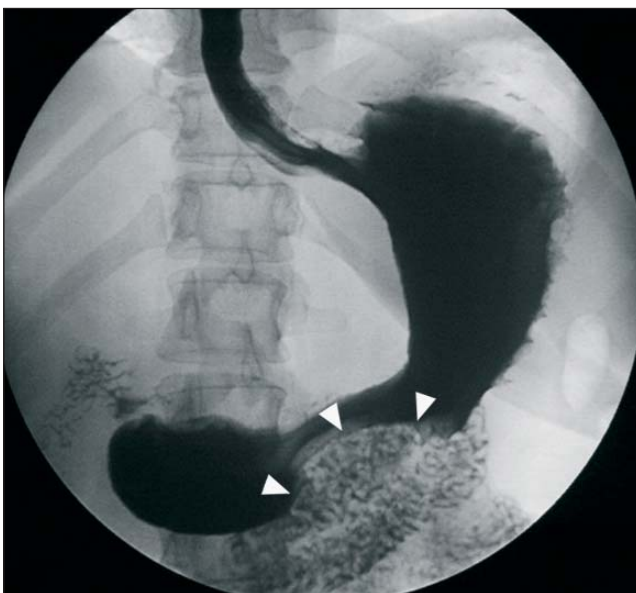


Figure 2
Radiofluoroscopy shows narrowing of the gastric lumen (arrowheads) highly suggestive of malignancy.

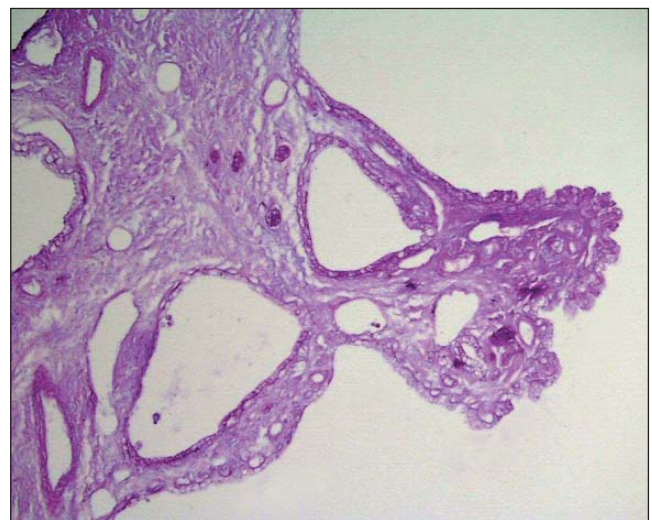


Figure 3
Histopathology shows a myriad of cysts lined by cuboidal AB/PAS-negative epithelium.

wall, therefore no resection procedure was performed on the stomach. At histology the cysts were lined by cuboidal normotypic epithelium, not staining for mucus (AB/PAS negative), which was consistent with the diagnosis of serous cystadenoma (Fig. 3). The gastric sample taken from antrum was not fibrotic and did not show cancer cells.

Discussion

Serous cystadenoma usually occurs in middle-aged or elderly females and is a benign tumour with

low potential for malignant change. This tumour usually is morphologically distinguishable from mucinous cystadenoma, which requires resection due to high malignant potential. Serous cystadenoma is primarily composed of a myriad of thin-walled small cysts (< 2 cm) or microcysts surrounding a central scar, which may be calcified (honeycomb appearance). Cysts, which are filled with watery fluid, are lined by a single layer of benign-appearing and glycogen-rich cuboidal epithelium (2). Small serous cystadenomas are most frequently found incidentally and may be

managed with observation alone. Larger cystadenomas are symptomatic in the majority of cases, may displace adjacent organs and undergo malignant transformation in up to 3 % of cases (7,9).

In our patient the size of cysts suggested mucinous cystadenoma and extension of this tumour to the stomach indicated locally advanced cystadenocarcinoma. However, this initial diagnosis was not confirmed by postsurgical histopathology of the entire tumour, which showed cysts lined by cuboidal epithelium, demonstrating no mucin or atypia.

Mimicking by benign cystic tumours of an invasive cystadenocarcinoma on CT or magnetic resonance is unusual. Japanese authors reported serous cystadenomas producing obstructive jaundice or left-sided portal hypertension (4,5). Moreover, Maire et al. (7) described 3 cases of entirely benign mucinous cysta-

denomas, which infiltrated the stomach, diaphragm or spleno-mesenteric vessels. These authors concluded, that as opposed to solid pancreatic masses, in case of cystic tumours pre-operative radiological signs of their extension into neighboring structures should not preclude surgery.

Several rare variants of serous cystadenomas have been distinguished, including predominantly solid, macrocystic, oligocystic or unilocular types (1, 3, 6, 8, 10). The reported patient presented oligocystic variant of serous cystadenoma, which in terms of general opinion cannot be definitely distinguished from mucinous cystadenoma and cystadenocarcinoma on the basis of imaging appearance, clinical symptoms, cytology or tumour markers (3,8). Therefore, final diagnosis of this neoplasm is still based on pathological examination after cyst removal.

REFERENCES

1. Ayadi-Kaddour A, Goutallier-Ben Fadhel C, Rezgui L, Lahmar-Boufaroua A, Levy P, Ruszniewski P, Flejou JF. Macrocystic form of serous pancreatic cystadenoma. *Am J Gastroenterol* 2002; 97: 2566-2571.
2. Brugge WR, Lewandrowski K, Lee-Lewandrowski E, Centeno BA, Szydlo T, Regan S, del Castillo CF, Warshaw AL. Diagnosis of pancreatic cystic neoplasms: a report of the cooperative cyst study. *Gastroenterology* 2004; 126: 1330-1336.
3. Chatelain D, Hammel P, O'Toole D, Terris B, Vilgrain V, Palazzo L, Belghiti J, Khalfallah MT, Mzabi-Regaya S. Unilocular macrocystic serous cystadenoma of the pancreas: a morphologic variant to be considered *Ann Chir* 2003; 128: 177-179.
4. Horaguchi J, Fujita N, Kobayashi G, Noda Y, Kimura K, Ito K, Kobari M, Yamazaki T. Serous cystadenoma of the pancreas associated with obstructive jaundice. *J Gastroenterol* 2003; 38: 501-506.
5. Iwasaki T, Nagata Y, Watahiki H, Yamamoto H, Ogawa H. A rare case of serous cystadenoma of the pancreas presenting with left-sided portal hypertension. *Surg Today* 1996; 26: 442-445.
6. Khurana B, Morteale KJ, Glickman J, Silverman SG, Ros PR. Macrocystic serous adenoma of the pancreas: radiologic-pathologic correlation. *Am J Roentgenol* 2003; 181: 119-123.
7. Maire F, Hammel P, Terris B, Vilgrain V, O'Toole D, Levy P, Belghiti J, Ruszniewski P. Benign inflammatory pancreatic mucinous cystadenomas mimicking locally advanced cystadenocarcinomas. Presentation of 3 cases. *Pancreatol* 2002; 2: 74-78.
8. Santos LD, Chow C, Henderson CJ, Blomberg DN, Merrett ND, Kennerson AR, Killingsworth MC. Serous oligocystic adenoma of the pancreas: a clinicopathological and immunohistochemical study of three cases with ultrastructural findings. *Pathology* 2002; 34:148-156.
9. Strobel O, Z'graggen K, Schmitz-Winnenthal FH, Friess H, Kappeler A, Zimmermann A, Uhl W, Buchler MW. Risk of malignancy in serous cystic neoplasms of the pancreas. *Digestion* 2003; 68: 24-33.
10. Yamamoto T, Takahashi N, Yamaguchi T, Imamura Y. A case of solid variant type of pancreatic serous cystadenoma mimicking islet cell tumor. *Clin Imaging* 2004; 28: 49-51.

Correspondence to:

Prof. dr hab. Marek Hartleb, Klinika Gastroenterologii, CSK, ul. Medyków 14, 40-752 Katowice, Poland.
E-mail: lakmus@poczta.wprost.pl